

# ABSENCE OF SUPERFICIAL PALMAR ARCH WITH PERSISTENT MEDIAN ARTERY - A CASE REPORT

Kavitha K.<sup>1</sup>, Sushma<sup>2</sup>, Prima D'Souza<sup>3</sup> & Vishal Kumar<sup>4</sup>

<sup>1,3</sup>Lecturers, <sup>2</sup>P. G. Student, <sup>4</sup>Associate Professor, Department of Anatomy  
K. S. Hegde Medical Academy, Nitte University, Mangalore 575 018, Karnataka, India.

Correspondence :

Kavitha K.

Lecturer, Department of Anatomy, K.S. Hegde Medical Academy, Nitte University, Mangalore - 575 018, Karnataka, India.

Mobile : +91 98449 02868 E-mail : kavithakshema@gmail.com

## Abstract:

The anatomical variations in the arterial supply of the palm are frequently reported. One such variation reported during routine dissection for undergraduate medical students in our college is the absence of superficial palmar arch and presence of persistent median artery. The arterial supply to the palm is in the form of superficial and deep palmar arches. In the present case the median artery and ulnar artery supplies the palm without forming an arch on the left extremity. Awareness of variations in the vascular pattern of the palm is clinically important in case of angiographic procedures and surgical emergencies.

Keywords : Superficial palmar arch, median artery, ulnar artery.

## Introduction:

The knowledge of different anatomical patterns of the superficial palmar arch is very important. The arterial supply to the palm is arranged into superficial palmar and deep palmar arches. The superficial palmar arch is of 2 types complete and incomplete. The median artery is the axis artery of the superior extremity during early embryonic life. If it persists in adults then it is referred as persistent median artery, which exists in 2 different patterns, palmar and antebrachial, based on their extent of supply.


The superficial palmar arch is formed by superficial terminal branch of the ulnar artery and can be completed on lateral side either by superficial palmar branch of the radial artery or the princeps pollicis artery or the radialis indicis artery or the median artery which accompanies the median nerve. From the convexity of superficial palmar

artery for the medial side of the little finger leaves the arch under palmaris brevis. The radial side of the index finger is supplied by the radialis indicis artery and the thumb is supplied by the princeps pollicis artery both of these are branches of the radial artery<sup>[1]</sup>.

## Case report:

The body of a 45-year old, formalin-fixed male cadaver was dissected as instructed in Cunningham's Manual of Practical Anatomy in the Department of Anatomy of our institution. The variation encountered is the absence of superficial palmar arch and persistent median artery which originated from the caudal angle between the ulnar artery and common interosseous trunk (Figure 1). In the upper third of the forearm, median artery pierced the median nerve from posterior to anterior. The superficial branch of radial artery was absent (Figure 2, 3).

The median artery coursed distally to lie alongside the median nerve in the upper third of the forearm and then continued its distal course between the anterior surface of the median nerve and the deep surface of flexor digitorum superficialis. In the upper third of the forearm, the median artery passed in front of the anterior interosseous nerve. The artery pierced the median nerve from posterior to anterior.



arch three common palmar digital arteries will arise and each one divides into two proper palmar digital arteries. These run along the contiguous sides of all four medial fingers to supply them. The palmar digital

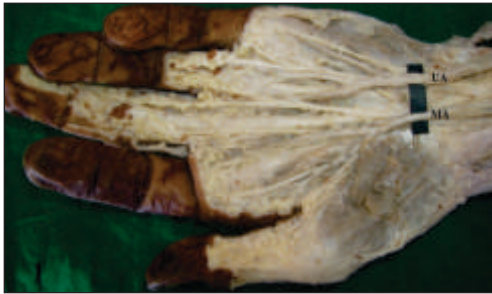

Figure 1 : Showing Left Unilateral Persistent Median Artery (Ua – Ulnar Artery, Ma – Median Artery)

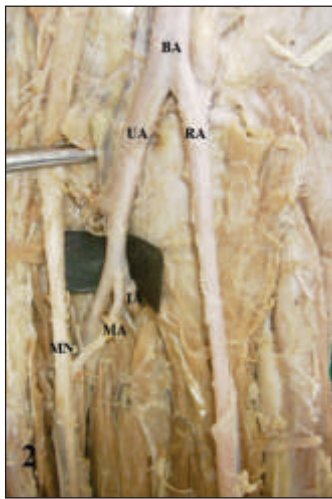


Figure 2: Showing The Origin Of Median Artery (Ba - Brachial Artery, Ua - Ulnar Artery, Ra - Radial Artery, Ma - Median Artery, Ia - Interosseous Artery, Mn - Median Nerve)

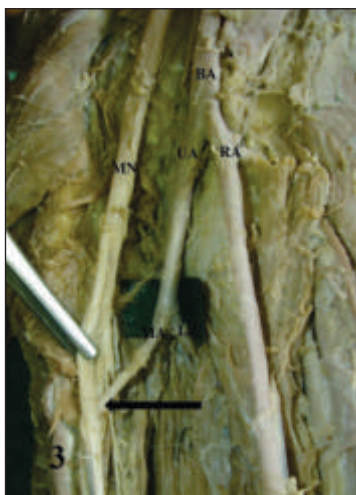


Figure 3: Showing The Relation Of Median Artery With The Median Nerve (Ba – Brachial Artery, Ua – Ulnar Artery, Ra – Radial Artery, Ma – Median Artery, Ia – Interosseous Artery, Mn – Median Nerve, Arrow- Showing The Entry Of Median Artery Between The Splitting Of Median Nerve)

In the distal third of the forearm the median artery emerged between the tendon of flexor carpi radialis and the middle finger tendon of flexor digitorum superficialis. At the wrist it passed deep to the flexor retinaculum, passed through the carpal tunnel and entered the palm.

Discussion:

The superficial palmar arch is situated beneath the palmar aponeurosis and it is superficial to the branches of the median nerve and to the long flexor tendons.

Gellman et al, classified the superficial palmar arch into two categories as complete and incomplete<sup>[2]</sup>. In complete arch, there will be an anastomosis between vessels constituting it. In incomplete arch there won't be any communication or anastomosis between the constituting vessels. In this case report, the ulnar artery gave one proper palmar digital artery to the medial side of little finger and two common palmar digital arteries which passed to the medial two interdigital clefts. The persistent median artery gave two common palmar digital arteries which passed to the lateral two interdigital clefts. The radial artery from the forearm was passing through anatomical snuff box to dip into first intermetacarpal space to take part in the formation of deep palmar arch. No superficial palmar branch, arteria princeps pollicis or arteria indices was arising from it. Since ulnar artery does not anastomose with the median artery, the superficial palmar arch is not formed.

Adachi has described 3 types of superficial palmar arch. Type A, B and C. The superficial palmar arch observed in the present case is Adachi's Type C (Median-ulnar type - in which arch is formed by the median artery and the larger ulnar artery)<sup>[3]</sup>.

Ikeda et al, demonstrated 96.4% complete and 3.6% incomplete forms. In this series, complete arches were seen in 75% and incomplete in 25% subjects<sup>[4]</sup>.

Coleman and Anson observed the complete form in 78.5% and incomplete form in 21.5% of 650 hands<sup>[5]</sup>. According to their classification, superficial palmar arch seen in the present case can be categorised to Group II (Incomplete

palmar arch) and Type C (Both median and ulnar arteries present but without anastomosis).

The incidence of median artery is between 1.5%-27.1%<sup>[6, 7, 8, 9, 10]</sup>. The origin of the median artery has been previously described as arising from the ulnar, interosseous, radial or brachial arteries<sup>[7, 10]</sup>. Two patterns of median artery termination have been described based on their vascular territory. The palmar type, which represents the embryonic pattern, is large, long and reaches the palm. The antebrachial type, which represents a partial regression of the embryonic artery is slender, short and terminates before reaching the wrist. The incidence of palmar type is 1.5-50% and the origin most common is common interosseous trunk (59%). The incidence of antebrachial type is 70-100% and the origin most frequently is anterior interosseous artery (55%). It is more frequent in females.

The median artery (MA) is the axis artery of the superior extremity during early embryonic life. It maintains the superficial palmar arch while the radial and ulnar arteries are developing<sup>[1]</sup>. The persistence of the median artery in the human adult has been considered as the retention of a primitive arterial pattern while the antebrachial pattern represents its partial regression<sup>[11, 12, 13]</sup>.

The clinical importance of the persistence of median artery

Reference:

1. Standring S, Ellis H, Healy JC, Johnson D, Williams A. Gray's Anatomy. 39th edn. 2005; 929. Churchill Livingstone, Edinburgh.
2. Gellman H, Botte MJ, Shankwiler J, Gelberman RH. Arterial patterns of the deep and superficial palmar arches. Clin Orthop Relat Res. 2001; 383:41-46.
3. Adachi B. Das Arteriensystem der Japaner. 1928; vol.1, pp. 285-356. Kyoto, Maruzen.
4. Ikeda A, Ugawa A, Kazihara Y, Hamada N. Arterial patterns in the hand based on a three-dimensional analysis of 220 cadaver hands. J Hand Surg. 1988;13:501-509.
5. Coleman, SS, Anson, BJ. Arterian patterns in the hand based upon a study of 650 specimens. Surg. Gynaecol. Obstet. 1961;113(4):409-424.
6. Sanudo JR, Chikwe J, Evans SE. Anomalous median nerve associated with persistent median artery. J Anat, 1994;185:447-451.
7. Quain R. The Anatomy of Arteries of Human Body. 1884. pp. 235- 271, London.
8. McCormack LJ, Cauldwell EW, Anson BJ. Brachial and Antebrachial arterial patterns: a study of 750 extremities. Surgery Gynecology and Obstetrics, 1953;96:43-45.
9. Srivastava SK, Pande BS. Anomalous pattern of median artery in the forearm of Indians. Acta Anatomica, 1990;138:193-194.
10. Henneberg M, George BJ. High incidence of the median artery of the forearm in a sample of recent South African cadavers. J Anat, 1992;180:185-188.
11. Chalmers J. Unusual cases of peripheral nerve compression. The Hand 1978;10:168-175.
12. Fumiere E, Dugardeyn C, Roquet ME, Delcour C. US demonstration of a thrombosed persistent median artery in carpal tunnel syndrome. JBR-BTR, 2002;85:1-3.
13. Muller E. Beitrage zur Morphologie des Gefasssystems. I. Die Arterien des Menschen. Anatomische Hefte 1903;22:377-575.
14. Keen JA. A study of the arterial variations in the limbs with special reference to symmetry of vascular patterns. American Journal of Anatomy. 1961;108,:245-261.
15. Rodriguez-Baeza A, Nebot J, Ferreira B, Reina F, Perez J, Sanudo JR. An anatomical study and ontogenic explanation of 23 cases with variations in the main pattern of the human brachio-antebrachial arteries. Journal of Anatomy. 1995;187:473-479.
16. De vriese B. Recherches sur evolution des vaisseaux sanguins des membres chez homme. Archives de Biologie 1902;18:665-730.
17. Singer E. Embryological pattern persisting in the arteries of the arm. Anatomical Record 1933;55:403-409.
18. Lanz T, Wachsmuth W. Praktische Anatomie, 1959; vol. 1, part 3, pp. 184-216. Springer, Berlin.

at wrist level is well documented as a cause of the carpal tunnel syndrome<sup>[14]</sup>. The incidence in which persistent median artery was apparent cause of carpal tunnel syndrome has been reported as 1.8%-6%<sup>[15]</sup>.

The other important relationship is the piercing of the median nerve by the median artery in the upper third of the forearm which has been reported. This vasculo-nervous relationship has been described in anatomical studies as an occasional finding<sup>[3, 6, 16]</sup> or with a markedly different incidence, ranging from 11% to 23%<sup>[8, 9, 17, 18]</sup>. This perforation of the nerve has been implicated in the pronator syndrome.

Conclusion:

The present case report has provided details about one of the variant of superficial palmar arch in humans. The knowledge of median-ulnar pattern of superficial palmar arch helps in accurate planning and better performance of surgical procedures in the forearm. Association of a persistent median artery with the median nerve should be considered in the evaluation of all patients with carpal tunnel syndrome. It is mandatory to conduct the investigations like Allen test, angiography and colour doppler studies of the hand before starting any invasive procedures including the vascular surgeries.